

PATIENT

Toby Gonzalez

SPECIES

Feline

BREED

DSH

SEX

Male Neutered

AGE

13 years

WEIGHT

5.5

INTERPRETED BY

Maggie Machen Lamy,
DVM, DACVIM
(Cardiology)

IMAGING PERFORMED BY

HOSPITAL NAME

Animal Emergency
Hospital of Deland

REFERRING VET

Dr. Kuzmiski

INVOICE

46043

DATE

12/4/25

PRESENTING CLINICAL SIGNS

History: Transferred for congestive heart failure and overnight care. P was diagnosed today at the rDVM who gave flow by oxygen and two injections of lasix while he was with them, the last injection was given prior to transfer. The plan is monitoring p overnight with oxygen support then O will transfer back to rDVM in morning for echocardiogram.

CXR report: moderate cardiomegaly, no CHF (post-lasix).

ELECTROCARDIOGRAPHIC FINDINGS *Note: Single lead ECGs are evaluated as a rhythm strip.

Morphology/MEA cannot be definitively commented on.

A single lead ECG is available; 25mm/s, 20mm/mV. The average heart rate is 200bpm. The rhythm is sinus in origin, with a p for every QRS complex and vice versa. The P and QRS morphologies are positive. No ectopic beats, pauses or other dysrhythmias observed.

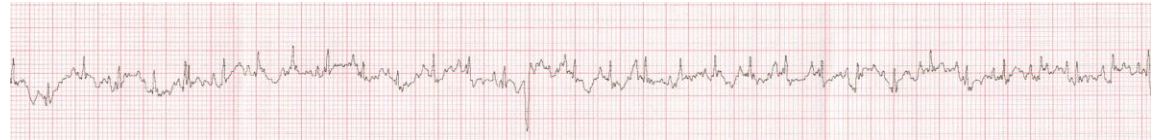
ECG diagnosis: Normal sinus tachycardia.

INTERPRETATION OF THE FINDINGS & FURTHER RECOMMENDATIONS

The submitted ECG is normal, with no evidence of dysrhythmias. If these findings do not reflect what was ausculted on exam (ie premature beats), a longer recording or potentially a holter monitor may be necessary.

Sinus tachycardia can be seen with CHF; however, this is quite non-specific and does not point towards any diagnosis for tachypnea. Follow up as dictated by the CXR/echo results.

IMAGES



The information and recommendations provided are based on the images presented by the referring veterinarian. No evaluation can be communicated regarding pathology that was not visible in the image/video clips provided.

Thank you for this referral. This report was generated using transcription software, and minor dictation errors may be present. If the clinical or image interpretation does not parallel your findings or if I can be of any further assistance, please contact me.

Maggie Machen Lamy, DVM

Diplomate of the American College of Veterinary Internal Medicine (Cardiology)

info@sonopath.com